

Simultaneous vascularized lymph node transfer and carpal tunnel release for treatment of advanced stage of breast cancer-related lymphedema with carpal tunnel syndrome

Dear Sir,

In advanced stages of upper extremity lymphedema (AUEL), increased volumes affect the hand causing mechanical impairment in routine daily activities. In addition, patients may experience numbness and pain at the distal aspect of the affected limb impairing the patient's functional and psychological status. Vascularized lymph node transfer (VLNT) has been reported as an effective physiological surgical procedure that improves the lymphatic circulation of the extremity, thus improving patient's quality of life (Ciudad et al., 2017; Gratzon et al., 2017). However, carpal tunnel syndrome (CTS) is a painful disorder caused by compression on the median nerve at the level of the carpal tunnel and carpal tunnel release (CTR) is the surgical treatment of choice (Badger, O'Donnell, Sherigar, Connolly, & Spence, 2008).

Although AUEL and CTS are different entities, the combination of increased interstitial and intracompartmental fluid due to the lack of adequate lymphatic outflow will augment the pressure over the median nerve, eventually worsening the symptoms related to CTS in patients with AUEL. The aim of this letter is to present a novel treatment of both entities with combined VLNT and CTR in one stage. This method was used in four patients with advanced stage breast cancer-related lymphedema who developed CTS.

EMG and nerve conduction studies confirmed CTS. Simple DASH test was performed pre- and 6 months postoperatively to evaluate hand functionality. All patients underwent simultaneous gastroepiploic

VLNT² and conventional open CTR. Improvement in limb circumference was documented in all patients post VLNT. Based on the DASH score, all patients noted improvement in the functionality of the hand (Figure 1). Symptoms relative to CTS were treated successfully and corroborated by EMG with no donor site morbidity or other postoperative complications.

The incidence of CTS in patients with lymphedema and whether lymphedema is a risk factor for CTS is still a matter of debate (Ganel, Engel, Sela, & Brooks, 1979; Stubblefield, Kim, Riedel, & Ibanez, 2015). Currently, there are no descriptions of simultaneous surgical treatment for CTS in patients with AUEL. The advantage of this combined technique is that both procedures can be performed from the same access site. The wide exposure allows better visualization and dissection around the median nerve, therefore decreasing the risk of nerve damage. The procedure is relatively fast, does not add significant time to the overall operation, and improves symptoms of both diseases. As both entities may present with similar symptomatology at the level of the hand, the key is accurate diagnosis with a combination of lymphoscintigraphy, EMG, and nerve conduction studies.

Based on these promising results, patients with AUEL and concurrent CTS may benefit from this novel combination of two well-established procedures in a single-stage operation. Long-term studies will further identify the safety and efficacy of this treatment option and clarify whether lymphedema is a risk factor for CTS.

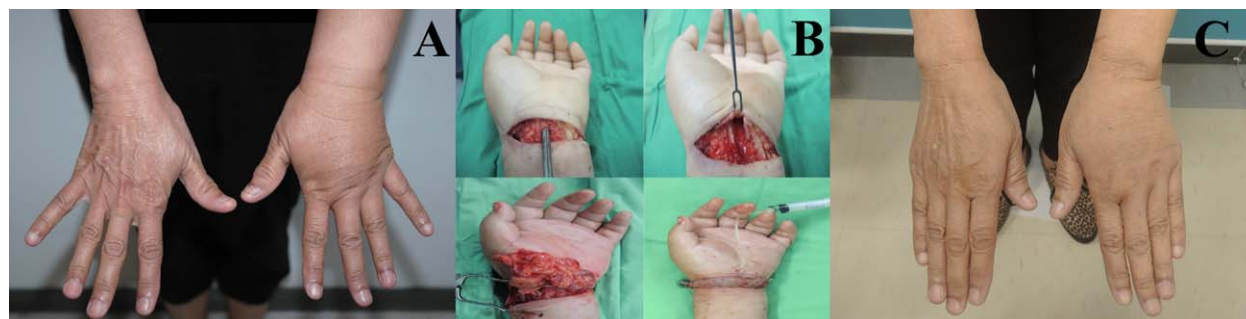

FIGURE 1 A, Preoperative photograph of a 51-year-old woman with left upper limb lymphedema and carpal tunnel syndrome. Patient underwent a simultaneous right gastroepiploic lymph node flap transfer to the left wrist and open carpal tunnel release. B, Intraoperative pictures of both procedures (above: carpal tunnel decompression, below: VLNT). C, At 16-month follow-up postoperative photograph (dorsal view) showed a significant circumference reduction rate of 31 and 35% at the wrist and hand level, respectively. In addition, patient reported improvement in the functionality of the hand and symptoms relative to carpal tunnel syndrome

ACKNOWLEDGMENTS



All authors hereby declare not to have any potential conflict of interests and not to have received funding for this work from any of the following organizations:

National Institutes of Health (NIH); Wellcome Trust; Howard Hughes Medical Institute (HHMI); and other(s). Each author participated sufficiently in the work to take public responsibility for the content.

Simultaneous Vascularized Lymph Node Transfer and Carpal Tunnel Release for Treatment of Advanced Stage of Breast Cancer-Related Lymphedema with Carpal Tunnel Syndrome.

CONFLICT OF INTEREST

None of the authors received any funds or has any financial interests to disclose.

Pedro Ciudad MD, PhD^{1,2} , Oscar J Manrique MD¹,
Shivprasad Date MBBS, MCh, DNB, MRCSEd¹ ,
Mouchammed Agko MD¹, Wei-Ling Chang BS¹,
Hung-Chi Chen MD, PhD¹

¹Department of Plastic and Reconstructive Surgery, China Medical University Hospital, Taichung, Taiwan

²Department of Biological Science and Technology, China Medical University, Taichung, Taiwan

Correspondence

Pedro Ciudad, MD, PhD., Department of Plastic Surgery, China Medical University Hospital, 2 Yuh-Der Road, Taichung 40447, Taiwan.
Email: pciudad@hotmail.com

Funding information

National Institutes of Health (NIH); Wellcome Trust; Howard Hughes Medical Institute (HHMI)

REFERENCES

- Gratzon, A., Schultz, J., Secrest, K., Lee, K., Feiner, J., & Klein RD. (2017). Clinical and Psychosocial Outcomes of Vascularized Lymph Node Transfer for the Treatment of Upper Extremity Lymphedema After Breast Cancer Therapy. *Annals of Surgical Oncology*, 24, 1475–1481.
- Ciudad, P., Maruccia, M., Socas, J., Lee, M. H., Chung, K. P., Constantinescu, T., ... Chen, H. C. (2017). The laparoscopic right gastroepiploic lymph node flap transfer for upper and lower limb lymphedema: Technique and outcomes. *Microsurgery*, 37, 197–205.
- Badger, S. A., O'Donnell, M. E., Sherigar, J. M., Connolly, P., & Spence, R. A. (2008). Open carpal tunnel release—still a safe and effective operation. *Ulster Medical Journal*, 77, 22–24.
- Stubblefield, M. D., Kim, A., Riedel, E. R., & Ibanez, K. (2015). Carpal tunnel syndrome in breast cancer survivors with upper extremity lymphedema. *Muscle Nerve*, 51, 864–869.
- Ganel, A., Engel, J., Sela, M., & Brooks, M. (1979). Nerve entrapments associated with postmastectomy lymphedema. *Cancer*, 44, 2254–2259.